

PennHIP Report

Referring Veterinarian: Dr John Shontz
Email: rspencer.sanfordah@yahoo.com

Clinic Name: Sanford Animal Hospital
Clinic Address: 200 West Seawell Street
Sanford, NC 27332
Phone: (919) 775-7945
Fax: (919) 776-2302

Patient Information

Client: Jones, Caron
Patient Name: Boom Boom

Tattoo Num:
Patient ID: 106411

Reg. Name: Singing Hills Fireworks O
Wagginnaire

Registration Num: RN23767205

PennHIP Num: 121056

Microchip Num: 985112000935950

Species: Canine

Breed: AIREDALE TERRIER

Date of Birth: 16 Jan 2012

Age: 24 months

Sex: Female

Weight: 56 lbs/25.4 kgs

Date of Study: 21 Jan 2014

Date Submitted: 13 Aug 2018

Date of Report: 14 Aug 2018

Findings

Distraction Index (DI): Right DI = 0.51, Left DI = 0.49.

Osteoarthritis (OA): No radiographic evidence of OA for either hip.

Cavitation/Other Findings: No cavitation present.

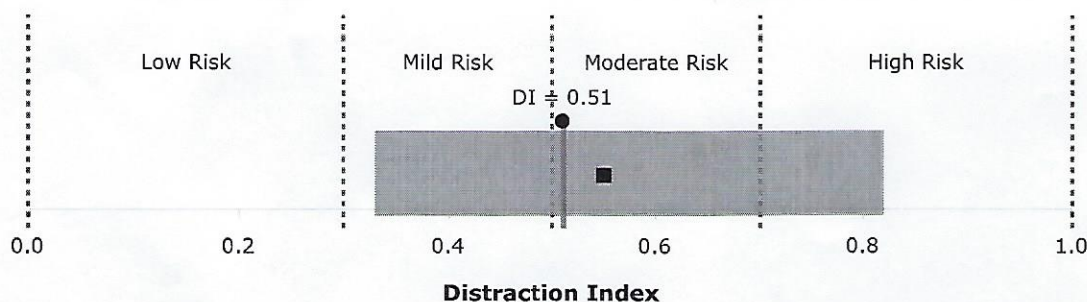
Interpretation

Distraction Index (DI): The laxity ranking is based on the hip with the greater laxity (larger DI). In this case the DI used is 0.51.

OA Risk Category: The DI is between 0.50 and 0.69. This patient is at moderate risk for hip OA.

Distraction Index Chart:

AIREDALE TERRIER



BREED STATISTICS: This interpretation is based on a cross-section of 1052 canine patients of the AIREDALE TERRIER breed in the AIS PennHIP database. The gray strip represents the central 90% range of DIs (0.33 - 0.82) for the breed. The breed average DI is 0.55 (solid square). The patient DI is the solid circle (0.51).

SUMMARY: The degree of laxity (DI = 0.51) falls within the central 90% range of DIs for the breed. This amount of hip laxity places the hip at a moderate risk to develop hip OA. **No radiographic evidence of OA for either hip.**